

**Case report:**

**Oesophageal perforation by gunshot - conservative surgical treatment**

Jorge Cabrera-Hinojosa MD, Juan de Dios Díaz-Rosales MD, Lenin Enríquez-Domínguez MD  
Pedro Arambula-Melendez MD

Surgery Service/Hospital General de Ciudad Juárez (Mexico)  
Post-graduate Division/Universidad Autónoma de Ciudad Juárez (Mexico)

**Introduction:**

Penetrating injuries such as gunshot wounds have been usual in Ciudad Juarez (Mexico), secondary to the expansion of organized crime like traffic of narcotics. Our surgical team (predominantly residents of surgery) obtain wide experience in their management. Oesophageal perforation is a rare, difficult to treat and a life-threatening condition with a mortality rate ranging between 10% and 40%. It can happen in all the oesophagus segments cervical, intrathoracic, or intra-abdominal. It usually occurs as a result of iatrogenic injury due to endoscopic procedures or as spontaneous rupture. It is seen less frequently in trauma after gunshot or stab wounds (1).

**Case presentation:**

A healthy 23-years-old man suffers a gunshot in neck during an assault. The Red Cross brought him to the General Hospital in Ciudad Juarez (Mexico), to receive medical attention. Surgery team was called to evaluate this patient in the emergency room. We found a patient in stable condition (hemodynamic and neurologic), without a fever, although irritable, he had subcutaneous emphysema, dysphagia, odynophagia, reactive cough, and sialorrhoea, with sanguineous sputum. We found a short neck, without evidence of vascular lesion and an entrance orifice at level of zone I lateral left side, while thorax, abdomen, arms, and legs without evidence of lesions. The complete blood count showed haemoglobin of 9.0mg/dl and he had high leukocyte count.

Neck radiography revealed subcutaneous emphysema, with predominance in left side and a bullet localized below cricoid cartilage and behind throat (Figure 1 and 2). Because of site and mechanisms of injury, we decided to explore to the cervical oesophagus in the operation room (OR). During transfer a broad-spectrum antibiotic was prescribed.

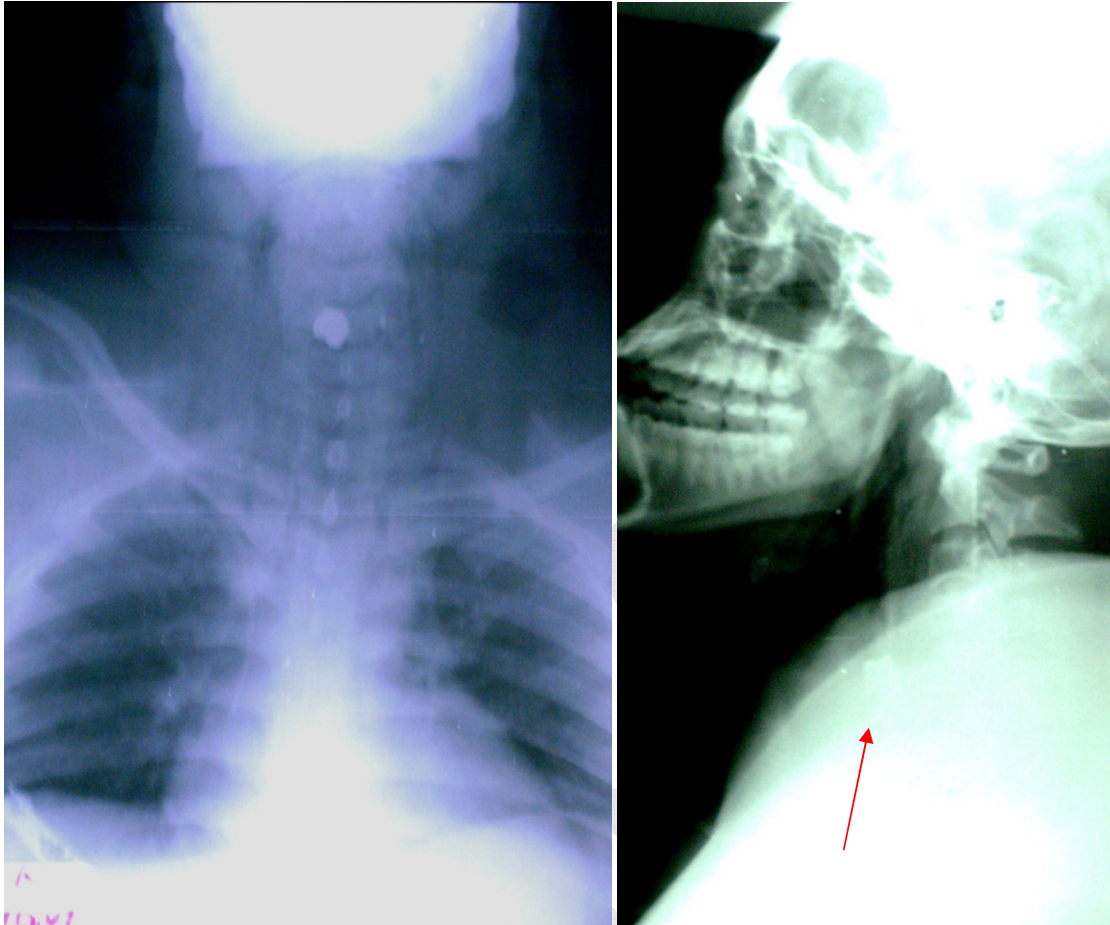


Figure 1 and 2: showed the bullet into lumen of oesophagus at level of zone one in the neck.

During his surgery, we found a penetrating wound (1 cm of diameter) at oesophagus cervical left side, and found a bullet inside of oesophagus, without lesion in right side wall of the organ. We repaired with absorbable suture in one plane in primary form. During the exploration, the bullet was found allocated 4cm below the wound and it went to the stomach without possibility to extract. During surgery, patient's vitals were stable, there was no more bleeding and a profuse saline solution wash was performed, this to decontaminate the area and to make sure no leakage was found; an open drainage was left next to the wound.

During his 8 days of hospitalization, the patient was in kept without any oral diet, with medication for analgesia, wide spectrum antibiotics, and ocreotide at doses of 50 mc/bid. In the 2nd day, he was initiated with total parenteral nutrition, without changes in physical examination and thorax radiography without mediastinum or in pulmonary parenchyma alterations.

At day 9, the patients started with oral feeding (liquids), with adequate tolerance, with progression on the diet until normal food. At 10th day of hospitalization, the patient was discharged to home in good shape, tolerating oral feeding and radiographic and laboratory controls in normal parameters. With medical date for check-up in 2 weeks, in his visit the patient continuous in good shape, without evidence of infection or other complication.

#### Discussion:

The modern approach to patients presenting with penetrating injuries to the neck requires the cautious integration of clinical findings and appropriate imaging studies for formulation of an effective, safe and, if it is necessary, invasive treatment (2). Despite progress in the management of oesophageal perforations by early diagnosis, antibiotics, monitoring, and respiratory and nutritional support, it still remains as a disastrous condition. The risk of oesophageal injury-related complications is directly related to the interval between the trauma and definitive management of the oesophageal injury (3).

Diagnosis of oesophageal injuries with dynamic CT scan is no better than oesophagography (4). Angiography plays a key role in the detection of a major vascular injury requiring surgical exploration. Careful clinical assessment enhanced with the appropriate investigations is the cornerstone for deciding to explore a gunshot wound to the neck (5). For centres like ours, with high gunshot trauma incidence, management of penetrating neck injuries include rapid diagnosis and definitive repair, and this should be the highest priority.

#### References:

1. Bazerbashi S, Villaquiran J, Bennett M, Unsworth-White MJ, Rahamim J. Stented esophageal transfixion injury. *Ann Thorac Surg* 2008;86:1367-9
2. Bagheri SC, Khan HA, Bell RB. Penetrating neck injuries. *Maxillofac Surg Clin North Am* 2008;20:393-414
3. Smakman N, Nicol AJ, Walther G, Brooks A, Navsaria PH, Zellweger R. Factors affecting outcome in penetrating oesophageal trauma. *Br J Surg* 2004;91:1513-19
4. Gonzalez RP, Falimirski M, Holevar MR, Turk B. Penetrating zone II neck injury: does dynamic computed tomographic scan contribute to the diagnostic sensitivity of physical examination for surgically significant injury? A prospective blinded study. *J Trauma* 2003;54:61-5
5. Van As AB, van Deurzen DF, Verleisdonk EJ. Gunshots to the neck: selective angiography as part of conservative management. *Injury* 2002;33:453-6

#### Corresponding author:

Cabrera-Hinojosa J  
Hospital General de Ciudad Juarez  
Country Mexico  
e-mail: [yors18@hotmail.com](mailto:yors18@hotmail.com)